

ICU GUIDELINE: MANUAL NASAL/ORAL DUODENAL FEEDING TUBE PLACEMENT

PREPARATION (BLUE BOX)

- Confirm indication; rule out contraindication.
- Obtain MD order to insert Entriplex Feeding Tube™ (EFT); clarify with MD if EFT to be inserted via the oral or nasal route.
- Obtain MD order for erythromycin* (250 mg IV); give via central access over 30 min, 15 - 30 min prior to EFT attempt.
- Review chest x-ray to ensure sump tip in optimal gastric position for decompression; reposition as required*.
- Place sump on suction for 5 min while gathering supplies.
- Explain procedure to patient.
- Place patient supine*.
- Provide sedation for patient comfort as indicated*.
- Prepare EFT (secure side port with multipurpose adapter/port cap – see supplies section); flush main port with 10 mL H₂O.
- Apply lubricant to EFT tip.

*UNLESS CONTRAINDICATED

INDICATIONS

- Gastric stasis (gastric residual volume >250 mL despite 24 hr trial of prokinetic).
- Aspiration risk (i.e. nursed in the supine or prone position).
- Severe acute pancreatitis.

CONTRAINDICATIONS

- Upper GI surgery.
- Significant GI bleed.
- Coagulopathies (nasal insertion).
- Facial fractures (nasal insertion).
- Basal skull fracture (nasal insertion).
- Esophageal varicities/diseases.
- Elevated ICP.
- Pharyngeal disorders.

SUPPLIES

Gloves	Goggles	Lubricant	#12 EFT
Stethoscope	Blue pads	Paper cups	Silk tape
pH paper	Tap water	Slip-tip syringe (60cc)	
Multipurpose Tubing Adapter		Male/Female Port Cap	

EFT INSERTION (PINK BOX)

STEP 1: PROXIMAL ESOPHAGUS (approx 25 cm)

Confirm tip position:

Auditory: Air injection: “burp” emitted from mouth. **Note:** If burp absent – remove EFT immediately.

STEP 2: GASTRIC POSITION (approx 55 cm)

Confirm tip position:

Auditory: Air injection/auscultation - muffled “swoosh” LUQ.

Tactile: Manual draw on plunger - no resistance; easy withdrawal of air and liquid returns.

Visual: Liquid returns - opaque pale yellow or light green.

Other: pH 1 – 5 (**Note:** pH not applicable if receiving PPI).

STEP 3: PYLORIC POSITION (approx 70 - 75 cm)

Insert EFT at 5 cm intervals (55 cm, 60 cm, etc)

Confirm tip position: (at each 5 cm interval).

Auditory: Air injection/auscultation - increasing clarity as tube moves right of midline into pylorus.

Tactile: a) Constant *very gentle* resistance as EFT inserted; EFT does not “spring back” when hand removed.

b) Manual draw on plunger - increasing resistance as EFT moves right of midline into pylorus.

Visual: Liquid returns – brighter yellow; returns may be difficult to obtain.

Other: pH ≥ 7 (**Note:** pH not applicable if receiving PPI).

STEP 4: DUODENAL POSITION (>85 cm)

Confirm tip position (initial):

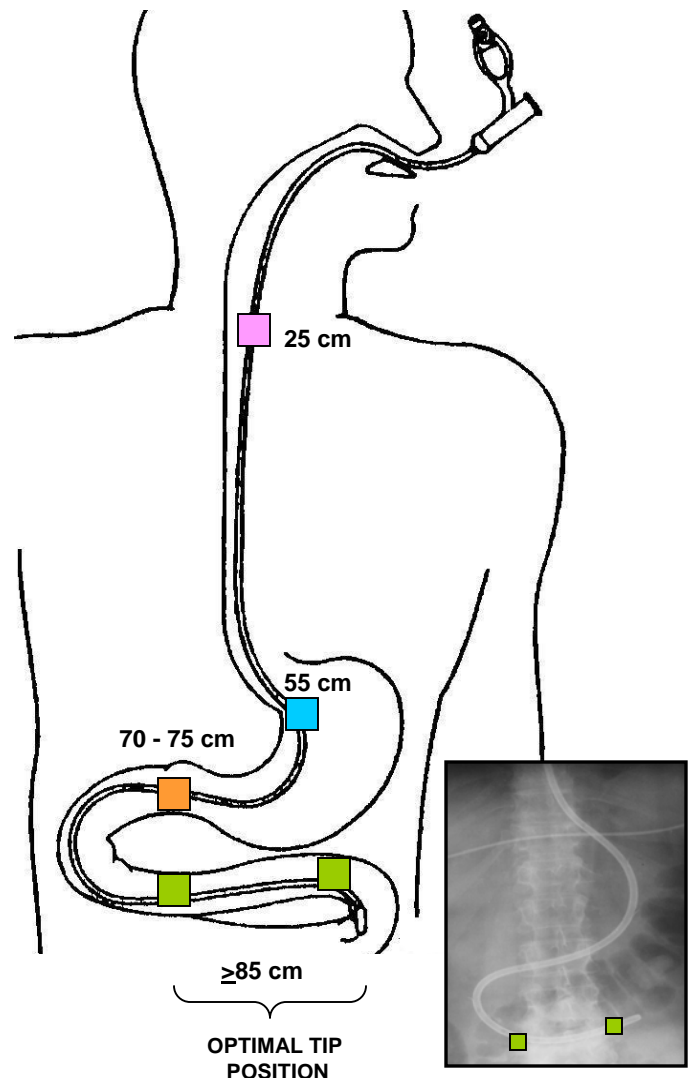
Auditory: Air injection/auscultation - high-pitched “squeal” followed by “tinkling” bowel sounds at or left of midline.

Tactile: Manual draw on plunger – some resistance; able to obtain liquid returns.

Visual: Liquid returns – very bright clear yellow.

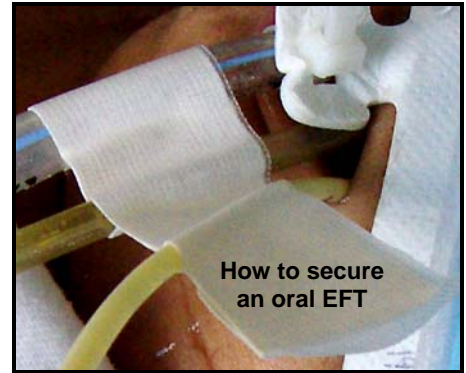
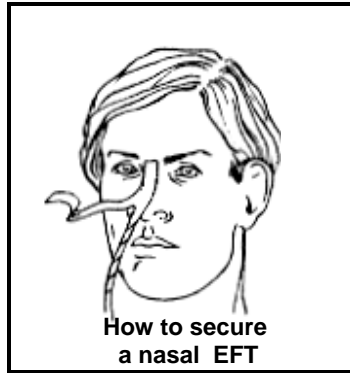
Other: pH ≥ 7. (**Note:** pH not applicable if receiving PPI).

STEP 5: CONFIRM TIP POSITION (See RED BOX→)



FINAL STEPS...

- 1) Obtain "abdominal x-ray for feeding tube placement"; request ICU Attending/Fellow review.
- 2) If EFT in pylorus, pull back to 55 cm mark; reattempt placement.
- 3) If EFT in optimal position a) print copy of x-ray, b) secure EFT (see diagram), and c) complete ND Placement Report - insert original in history section of patient chart; place copy with x-ray print-out attached in ND QI/QA binder.
- 4) Obtain MD order to resume feeds (refer to ICU Guideline: EN Post Pyloric Feeding for details).



	<u>PROBLEM</u>	<u>THE DIFFICULT TUBE – PROBLEM SOLVING TIPS</u>
<div style="background-color: #FFB6C1; width: 15px; height: 15px; display: inline-block; margin-right: 5px;"></div> Upper esophagus	<p>Unable to insert EFT into nostril</p> <p>EFT coils in back of throat</p>	<ol style="list-style-type: none"> 1) If patient does not have a nasally inserted gastric sump, try both nostrils to determine the most patent nare. To insert, direct EFT tip straight back into nostril; at point of resistance, gently rotate (roll) EFT while slowly inserting. If unsuccessful... 2) Insert EFT into same nostril as gastric sump. If unsuccessful.. 3) Insert EFT via the oral route. If unsuccessful abort attempt. <hr/> <ol style="list-style-type: none"> 1) Elevate HOB 90°; tuck chin into the chest (tipping head slightly to the right may be helpful). Insert EFT. If unsuccessful... 2) Sedate patient. Insert two fingers into oral pharynx; gently pull tongue forward. Using the two fingers, locate EFT and gently guide EFT between fingers beyond the pharynx. If unsuccessful... 3) Request MD insert using direct visualization (i.e. Laryngoscope or Glidescope) If unsuccessful... 4) Attempt EFT insertion via the oral route. If unsuccessful abort attempt.
<div style="background-color: #00B0F0; width: 15px; height: 15px; display: inline-block; margin-right: 5px;"></div> Gastric	<p>EFT at 55 - 60 cm mark but "muffled whoosh" absent LUQ</p>	<p>A) Tube coiled in throat?</p> <ol style="list-style-type: none"> 1) Inject 20 cc air into EFT. If "burp" present, EFT is coiled in back of throat. Pull back EFT and re-attempt insertion. If burp absent ... <p>B) Tube in airway?</p> <ol style="list-style-type: none"> 1) If "burp" absent, hold EFT tip to ear. If air expiration noted, EFT is in airway. Remove EFT. Reattempt insertion. If burp and air expiration absent... <p>C) Tube in distal esophagus?</p> <ol style="list-style-type: none"> 1) Insert EFT by an additional 10 cm (NOTE: Abort attempt if any significant resistance); re-attempt confirmation (air injection and auscultation). 2) If still unclear, obtain a "chest x-ray for feeding tube placement".
<div style="background-color: #FFA500; width: 15px; height: 15px; display: inline-block; margin-right: 5px;"></div> Pylorus	<p>EFT at 70 - 75 cm mark; "muffled whoosh" remains LUQ.</p> <p>EFT at 70 - 75 cm mark; clear high-pitched sound right of midline but "tinkling" bowel sounds absent.</p>	<p>A) Tube coiled in fundus?</p> <ol style="list-style-type: none"> 1) Pull back EFT to 55 cm mark. Gently re-insert while slowly rotating (rolling) EFT. Confirm EFT tip position with air injection and auscultation. If unsuccessful... 2) Reposition patient right side down (unless contraindicated). Pull back EFT to 55 cm mark. Attempt re-insertion as noted above. If unsuccessful, abort attempt. <hr/> <p>B) EFT tip "stuck" in pylorus?</p> <ol style="list-style-type: none"> 1) Flush EFT with 30 mL tap water to attempt to lift EFT tip off bowel wall. Continue to insert EFT to 85 cm mark while gently rotating EFT tip. If unsuccessful... 2) Remove wire; secure EFT (see RED BOX above). Flush EFT with 30 mL tap water. Obtain an "abdominal x-ray for feeding tube placement" in 1 hr. If unsuccessful... 3) Review x-ray to ensure 5 - 10 cm of excess loose EFT (no kinks or tight coils) sitting within the stomach with EFT tip in pylorus. Secure EFT (see RED BOX above). Obtain MD order for a 2nd dose of erythromycin*. Obtain an "abdominal x-ray for feeding tube placement" in 2 - 4 hrs. If unsuccessful abort attempt.
<div style="background-color: #90EE90; width: 15px; height: 15px; display: inline-block; margin-right: 5px;"></div> Small bowel	<p>On x-ray ETF tip < 2nd section duodenum</p>	<p>Unable to reposition EFT from proximal to distal duodenum.</p> <ol style="list-style-type: none"> 1) Secure EFT. Remove wire. Flush EFT with 30 mL tap water to lift EFT tip off bowel wall and stimulate peristalsis. Obtain an "abdominal x-ray for feeding tube placement" in 1 hr. If unsuccessful... 2) Abort attempt. Use tube as is. Consider initiating/continuing a prokinetic.